

## 3D Detected a Missed IUD Despite Threads at the Cervix in Post Caesarean Section Delivery: A Case Report

Firoozeh Ahmadi,<sup>1\*</sup> Somayeh Moukhah,<sup>1</sup> Farnaz Akhbari,<sup>1</sup> and Firouzeh Ghaffari<sup>2</sup>

<sup>1</sup>Department of Reproductive Imaging, Reproductive Biomedicine Research Center, Royan Institute for Reproductive Biomedicine, ACECR, Tehran, Iran

<sup>2</sup>Department of Endocrinology and Female Infertility, Reproductive Biomedicine Research Center, Royan Institute for Reproductive Biomedicine, ACECR, Tehran, Iran

\*Corresponding author: Firoozeh Ahmadi, Department of Reproductive Imaging, Reproductive Biomedicine Research Center, Royan Institute for Reproductive Biomedicine, ACECR, Tehran, Iran. Tel: +98-21235624 46, Fax: +98-2123562172, E-mail: dr.ahmadi390@gmail.com

Received 2016 August 29; Revised 2016 November 16; Accepted 2016 December 01.

### Abstract

**Introduction:** Intrauterine devices (IUDs) have been used as a commonly convenient, efficient, relatively safe, and inexpensive method of contraception worldwide. Contraceptive efficacy is related to intrauterine location of IUD. Insertion of IUD without prior pelvic evaluation by ultrasound is a predisposing factor for unsuitable placement and may reduce contraception effectiveness.

**Case Presentation:** We present a patient who referred to Royan institute in Tehran (Iran) with IUD displacement due to an inappropriate insertion of the device into her recent cesarean section scar.

**Conclusions:** IUD displacement into the myometrium could be done in clinics, but advanced laparoscopy is needed for confirmed diagnosis and IUD complication management. Three-dimensional transvaginal ultrasound (3DTVUS) clearly displays the correct position of the IUD in the uterine cavity much better than the two-dimensional transvaginal ultrasound (2DTVUS).

**Keywords:** Displacement of IUD, Post Cesarean Section, Three-Dimensional Ultrasound, Two-Dimensional Ultrasound

### 1. Introduction

Intrauterine devices (IUDs) are a common and highly effective method of contraception (1). Relevant complications of IUDs include pain and bleeding, malposition (perforation, displacement, embedment, and expulsion), pelvic inflammatory disease, and ectopic pregnancy (2). The complications of translocation are varied with a wide range of the spectrum, from displacement of IUD in myometrium to uterine perforation. Uterine perforation is uncommon but serious (3). Risk factors associated with perforation include the clinicians' lack of experience, insertion in women who are lactating, and the abnormalities in the cervix or uterus (4).

A regular medical checkup is necessary to determine the IUD position within the uterus up to 6 months after IUD insertion. Clinical history, physical examination, and transvaginal ultrasonography (US) are common procedures for evaluating IUDs and related complications (5).

Sonography plays an important role in assessing the complications of IUDs. The associated complication with IUDs includes low position, myometrial embedment, uterine perforation, intrauterine or extra uterine pregnancy associated with the IUD, and associated infection. IUD should be centrally located within the endometrial cavity, with the crossbar (if present) in the fundus of the endometrial cavity. Although two-dimensional ultrasound (2DUS) is a standard method in practice, it has restricted value for verify-

ing the two arms of IUD within the same plane; hence, detection of IUD displacement is failed by 2DUS (6). Coronal view could be detected by three-dimensional sonography (3DUS), so this method is particularly helpful to find the shaft and the both horizontal arms in a single plane (5). In symptomatic patients with pelvic pain or abnormal bleeding, sometimes IUDs, which appeared to be placed correctly or low on 2D ultrasound, were found to be imbedded within the myometrium with further investigation using 3DUS or hysteroscopy (7-9). If an IUD is present but not visible sonographically plain radiography is helpful in assessing its location. The associated complication of IUDs such as abscess formation, visceral perforation, and intestinal injury could be assessed by computed tomography (CT). Magnetic resonance imaging is not typically used to assess IUDs. Many studies demonstrated the effectiveness of 3DUS in determining IUDs' location, particularly for symptomatic patients. Lee et al. detected a complete image of IUDs in 95% of the patients on 3DUS vs. 64% on 2DUS (10). Valsky et al. reported that 3DUS is of great help in symptomatic patients when the location of IUD cannot be correctly identified with traditional 2DUS (11). Furthermore, Bonilla-Musoles et al. confirmed this result and demonstrated that 2DUS failed to identify the position of IUDs in 3%, and misidentified IUDs in 12% of the patients, which was later confirmed on 3DUS (6).

This rare case study was presented to introduce the displacement of IUD out of the uterine cavity through

previous cesarean section scar between serosa and myometrium due to inappropriate technical insertion.

## 2. Case Presentation

In March 2015, a 30-year-old female, Para 1, Abortion 0 without any specific chief complaints referred to Royan institute (Tehran, Iran) to check her IUD. She had a body mass index (BMI) of 24.8 and her vital signs were checked and recorded (blood pressure: 110/70 mmHg and pulse rate: 71). To assess the position of the IUD, she was referred to the imaging department. The patient had an obstetric history of a prior cesarean delivery of a set of twin pregnancy 8 months earlier and was amenorrhic due to her lactation. She underwent intrauterine device (IUD) insertion while lactating. The patient was followed up 6 weeks after insertion. The string was not found at the pelvic examination. All procedures performed in studies involving human participants were in accordance with the ethical standards of Royan institute. Consent form was obtained from the patient.

2DUS was performed and a vague image of IUD was seen in the cervical canal, but nothing was found in the uterus cavity. A suspicious image of IUD was found out of the uterus with surrounding collection (Figures 1 - 3). Subsequently, images were obtained with transvaginal (TV) 3D probe (5-8MHZ-Accuvix XQ, Medison Company, South Korea machine). Using this method, the acoustic shadow of the IUD and its position were clearly visible and found to be positioned partially in the endocervical canal which was displaced into the cesarean scar defect, extending laterally to the myometrium near to the serosa with fluid collection (Figures 1 and 2). The patient was hospitalized for observation. As there were not any symptoms, it was assumed that IUD was introduced to the scar defect from the beginning of the insertion of the IUD and after being inserted into the cervix; then it was displaced out of the uterine cavity at the serosal level of uterus. An expert gynecologist who performed the laparoscopy confirmed the findings revealed by the 3DUS (Karl Storz GmbH and Co., Tuttlingen, Germany). Three access openings were created which were as follow: One 10-mm diameter opening at the umbilicus, one 5-mm opening in the left lateral abdomen, and a 5-mm opening in the suprapubic. Exploratory laparoscopy was performed. The viseral peritoneum was found to be adherent to the anterior lower uterine surface above the bladder reflection. When those adhesions were separated, an intrauterine device of the TCu 380A was found protruded from the lower uterine segment serosa. It was dissected free and removed. There was no evidence of damage to the bladder or the bowel. The operation was uneventful, and

the patient was fully recovered and discharged the next day.

## 3. Discussion

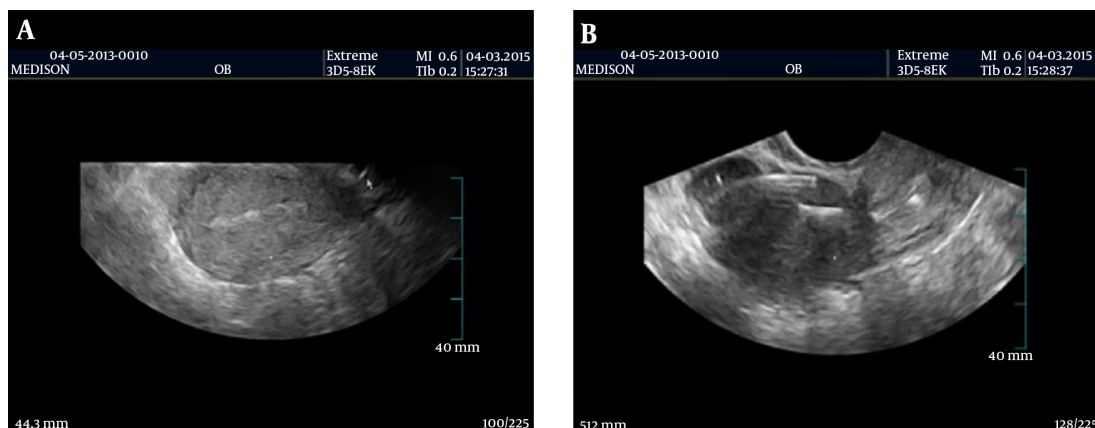
IUD displacement is a common problem in women with intrauterine conception device and occurs in up to 25% of these women (12, 13). Although IUD displacement is usually asymptomatic, some patients complain about cramping or bleeding. Another complication of IUD that was mentioned previously is perforation, which is uncommon but serious and occurs in up to one of every 1000 cases (3). The extent of IUD perforation is variable, ranging from embedment into the myometrium to complete transuterine perforation with migration of the IUD into the myometrium to the peritoneal cavity (7, 14). In this case report, displacement of IUD might have been misdiagnosed with perforation (the most common complication is omental adhesion formation) since the shaft of IUD was visible in the cervix by 2DUS, but the arms were better observed using 3DUS, which showed the displacement out of the cavity through previous cesarean section scar into the peritoneal cavity. The prominence specified in this patient was that initially IUD displacement occurred through the open scar of the previous cesarean section while the length of the thread was normal and IUD was not in the uterine cavity.

Various imaging methods can be utilized to evaluate IUDs. US as an available and inexpensive method is used for initial evaluation, and it does not involve radiation. 2D US is suitable for detecting the stem, but 3D US is often adequate for identifying the location of the arms of the IUD with respect to the uterine cavity. In the current study, considering the coronal view in the three-dimensional ultrasound results, we emphasized the importance of applying three-dimensional ultrasound in finding the precise location of IUD in women with cesarean section scars.

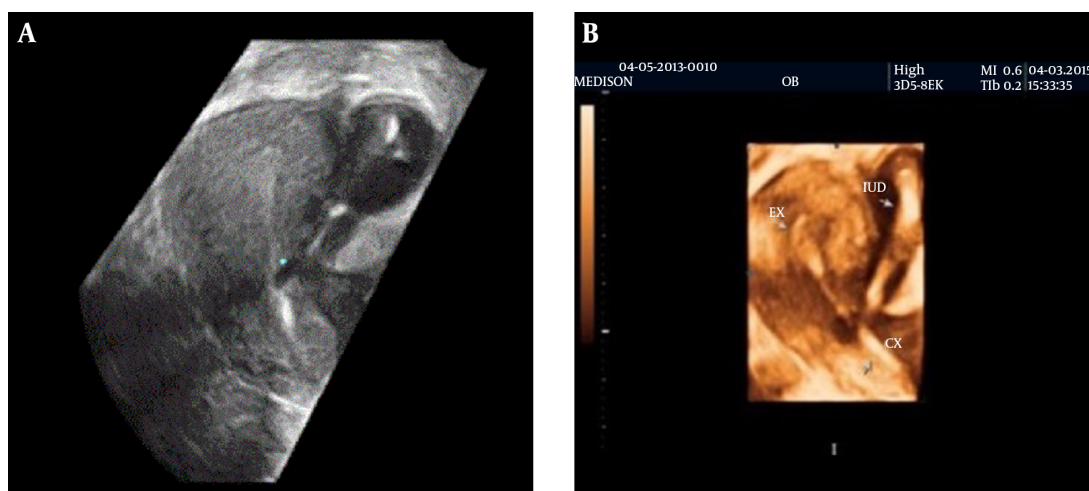
Abdominal radiography and pelvic x-ray could be useful in demonstrating an extra uterine IUD and are required for the diagnosis of IUD expulsion. Magnetic resonance (MR) imaging is not typically used for evaluating IUD position, but CT is a useful modality for demonstrating complications of IUD.

### 3.1. Conclusion

3DUS is often helpful for further characterizing the findings of IUD complications and it has become a routine method for evaluation of IUDs. Conventional radiography of the abdomen and pelvic are used to assess the location of an IUD when it is not clearly visible at US. The radiologists should be familiar with any findings of IUD malpositioning.



**Figure 1.** Sagittal view of 2DUS depicts no IUD in uterine cavity (A) and 2DUS demonstrates a malpositioned partial shaft of IUD (arrow) in the cervix. Remained shaft and arms of IUD were visible in the uterine cavity (B).



**Figure 2.** A, The Coronal view of 3DUS shows that the IUD was positioned partially in the endocervical canal (a) and extending laterally to the myometrium and serosa with fluid collection, (b) IUD displaced into the cesarean scar defect; B, 3DUS view shows IUD in extrauterine location.



**Figure 3.** Schematic View of IUD Displacement

### Acknowledgments

The authors wish to thank the staff of imaging department for their assistance in figure preparation.

### Footnotes

**Authors' Contribution:** All the authors participated sufficiently to take public responsibility for the content.

**Financial Disclosure:** No financial interest influenced or interfered with the research findings.

**Funding/Support:** There were not any relevant financial or nonfinancial relationships in the products or services

described, reviewed, evaluated, or compared in this presentation.

## References

1. Tatum HJ. Intrauterine contraception. *American J Obstet Gynecol.* 1972;**112**(7):1000–23. doi: [10.1016/0002-9378\(72\)90828-9](https://doi.org/10.1016/0002-9378(72)90828-9).
2. Peri N, Graham D, Levine D. Imaging of intrauterine contraceptive devices. *J Ultrasound Med.* 2007;**26**(10):1389–401. [PubMed: [17901142](https://pubmed.ncbi.nlm.nih.gov/17901142/)].
3. Harrison-Woolrych M, Ashton J, Coulter D. Uterine perforation on intrauterine device insertion: is the incidence higher than previously reported?. *Contraception.* 2003;**67**(1):53–6. [PubMed: [12521659](https://pubmed.ncbi.nlm.nih.gov/12521659/)].
4. Caliskan E, Ozturk N, Dilbaz BO, Dilbaz S. Analysis of risk factors associated with uterine perforation by intrauterine devices. *Eur J Contracept Reprod Health Care.* 2003;**8**(3):150–5. [PubMed: [14667326](https://pubmed.ncbi.nlm.nih.gov/14667326/)].
5. Ahmadi F, Haghighi H. The role of three-dimensional imaging in the control of intrauterine contraceptive devices. *Iran J Radiol.* 2015;**12**(2) doi: [10.5812/iranjradiol.8499](https://doi.org/10.5812/iranjradiol.8499).
6. Bonilla-Musoles F, Raga F, Osborne NG, Blanes J. Control of intrauterine device insertion with three-dimensional ultrasound: is it the future?. *J Clin Ultrasound.* 1996;**24**(5):263–7. doi: [10.1002/\(SICI\)1097-0096\(199606\)24:5<263::AID-JCU6>3.0.CO;2-C](https://doi.org/10.1002/(SICI)1097-0096(199606)24:5<263::AID-JCU6>3.0.CO;2-C). [PubMed: [8723515](https://pubmed.ncbi.nlm.nih.gov/8723515/)].
7. Shipp TD, Bromley B, Benacerraf BR. The width of the uterine cavity is narrower in patients with an embedded intrauterine device (IUD) compared to a normally positioned IUD. *J Ultrasound Med.* 2010;**29**(10):1453–6. [PubMed: [20876899](https://pubmed.ncbi.nlm.nih.gov/20876899/)].
8. Graupera B, Hereter L, Pascual MA, Fernandez-Cid M, Urbina C, Di Paola R, et al. Normal and abnormal images of intrauterine devices: Role of three-dimensional sonography. *J Clin Ultrasound.* 2012;**40**(7):433–8. doi: [10.1002/jcu.21955](https://doi.org/10.1002/jcu.21955). [PubMed: [22729850](https://pubmed.ncbi.nlm.nih.gov/22729850/)].
9. Benacerraf BR, Fleischer AC. Three-dimensional volumetric sonography in gynecology. In: Fleischer AC, Toy EC, Lee W, Manning FA, Romero R, editors. *Sonography in obstetrics & gynecology: Principles and practice.* 7th ed. New York: Mc Graw Hill; 2011. .
10. Lee A, Eppel W, Sam C, Kratochwil A, Deutinger J, Bernaschek G. Intrauterine device localization by three-dimensional transvaginal sonography. *Ultrasound Obstet Gynecol.* 1997;**10**(4):289–92. doi: [10.1046/j.1469-0705.1997.10040289.x](https://doi.org/10.1046/j.1469-0705.1997.10040289.x). [PubMed: [9383883](https://pubmed.ncbi.nlm.nih.gov/9383883/)].
11. Valsky DV, Cohen SM, Hochner-Celnikier D, Lev-Sagie A, Yagel S. The shadow of the intrauterine device. *J Ultrasound Med.* 2006;**25**(5):613–6. [PubMed: [16632785](https://pubmed.ncbi.nlm.nih.gov/16632785/)].
12. Moschos E, Twickler DM. Does the type of intrauterine device affect conspicuity on 2D and 3D ultrasound?. *AJR Am J Roentgenol.* 2011;**196**(6):1439–43. doi: [10.2214/AJR.10.5483](https://doi.org/10.2214/AJR.10.5483). [PubMed: [21606311](https://pubmed.ncbi.nlm.nih.gov/21606311/)].
13. Zakin D, Stern WZ, Rosenblatt R. Complete and partial uterine perforation and embedding following insertion of intrauterine devices. I. Classification, complications, mechanism, incidence, and missing string. *Obstet Gynecol Surv.* 1981;**36**(7):335–53. [PubMed: [7029368](https://pubmed.ncbi.nlm.nih.gov/7029368/)].
14. Bennis H, Berraho K, Kouarty I, Omrani H, Filali A, Saadi N, et al. [Transuterine migration of intrauterine contraceptive devices]. *Rev Med Liege.* 2011;**66**(3):153–8. [PubMed: [21560432](https://pubmed.ncbi.nlm.nih.gov/21560432/)].